



Patient	NHS No
D.O.B.	Patient Ref

Reason	Varicose vein
Outcome	Incompetence

	Right		Left	
Deep Veins	Patency	Competency	Patency	Competency
Common Iliac Vein				
External Iliac Vein				
Internal Iliac Vein				
Common Femoral Vein			Widely Patent	Competent
Profunda Vein			Widely Patent	Competent
Superficial Femoral Vein			Widely Patent	Competent
Popliteal Vein			Widely Patent	Competent
Posterior Tibial Vein			Widely Patent	Competent
Anterior Tibial Vein			Widely Patent	Competent
Peroneal Vein			Widely Patent	Competent
Soleal Vein				
Gastrocnemius			Widely Patent	Competent
Superficial Veins				
Saphenofemoral Junction			Widely Patent	Incompetent
L Saphenous Vein Above			re-form	Incompetent
L Saphenous Vein Below			Widely Patent	Isolated Incompetence
Vein of Giacomini			Not Identified	
Saphenopopiteal Junction			Not Identified	
S Saphenous Vein			Widely Patent	Competent
Evidence of D.V.T.				
Above the knee			No	
Popliteal			No	
Below the knee			No	

Notes

LEFT LOWER LIMB VENOUS DUPLEX ASSESSMENT

Iliac veins not viewed. Flow in the common femoral vein is phasic with respiration and a normal response on Valsalva manoeuvre, suggesting proximal vein patency. All visualised deep veins appear widely patent and competent with no evidence of previous DVT.

All measurements are proximal to the medial malleolus unless otherwise stated.

Sapheno-femoral junction (SFJ) is incompetent. Neo-vascularisation noted at the groin with proximal long saphenous vein (LSV) not identified ?previous surgery. The LSV re-forms in the prox-mid thigh (~61cm) and is incompetent. LSV is linear for ~9cm, before becoming superficial and tortuous in the distal thigh (~52cm). Multiple incompetent branches leave the superficial LSV to form the visible varicosities of the anterior thigh and knee. A relatively large (0.5cm TS), but competent anterior thigh vein tracks inferiorly and conflues

Assessed by Lukasz Koprowski

Checked by _____



Patient

NHS No

D.O.B.

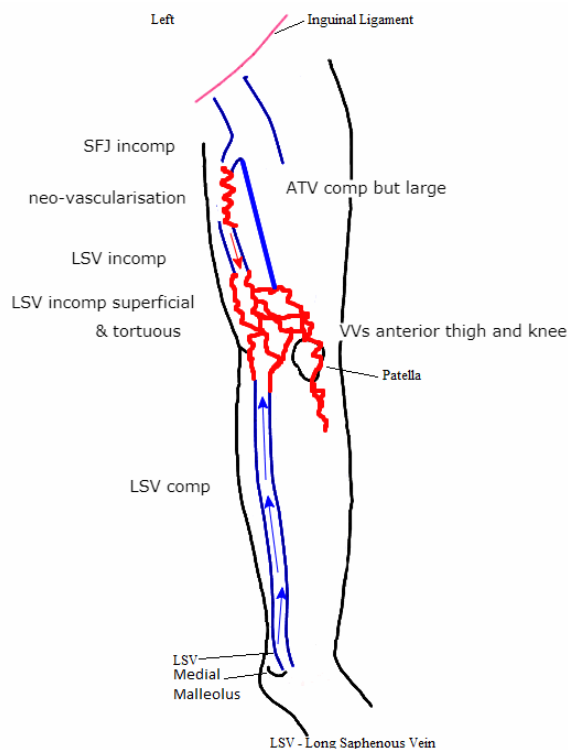
Patient Ref

the anterior thigh varicosities.

LSV re-enters its fascia in the proximal calf (~23cm) and is competent for the remainder of its course within the mid and distal calf.

Sapheno-popliteal junction (SPJ) was not identified. A relatively large, but competent, proximal short saphenous vein (SSV) (~0.7cm TS) appears drain into one of the competent sets of gastrocnemius veins. After the initial, proximal ~2cm, the SSV appears to be small and competent.

Transverse (AP) dimensions of LSV: Prox-mid thigh 0.4cm.



Assessed by

Lukasz Koprowski

Checked by